



Reconstruction of lateral attic wall in acquired cholesteatoma

Rekonstrukcija lateralnog zida atika kod stečenog holesteatoma

Milan Erdoglija*, Milanko Milojević*, Uglješa Grgurević*, Jelena Sotirović*,
Nada Milanović*, Snežana Cerović†‡, Milena Jović†, Nenad Baletić**

*Ear, Nose and Throat Clinic, †Institute of Pathology, Military Medical Academy,
Belgrade, Serbia; ‡Faculty of Medicine of the Military Medical Academy, University of
Defence, Belgrade, Serbia

Abstract

Background/Aim. Attic cholesteatoma is an epithelial cystic pseudotumor which arises in the top compartment of the middle ear. Surgery is the only therapeutic treatment for attic cholesteatoma. The aim of this study was to analyze the surgical and audiological results in tympanoplasties that use a logical application of several techniques for the management of attic cholesteatoma. Our hypothesis was that the tympanoplasty technique with cartilage/bone reconstruction of the achieve better outcome than the tympanoplasty technique with only temporal fascia reconstruction of the lateral attic wall. **Methods.** This retrospective clinical study included 80 patients, aged 16–65 years, with attic cholesteatoma undergoing canal “wall up” tympanoplasty with lateral attic wall reconstruction, under general anesthesia in the Ear, Nose and Throat Clinic, Military Medical Academy in Belgrade between 2006 and 2010. The patients were divided into two groups according to the type of lateral attic wall reconstruction: the group I of 60 patients with cartilage/bone plus temporalis fascia lateral attic wall reconstruction and the group II of 20 patients with only temporal fascia lateral attic wall reconstruction. Postoperative follow-up examinations were done at least 5 years after the surgery. The χ^2 test was used to compare postoperative sequelae for two groups of operated patients with lateral attic wall reconstruction.

Apstrakt

Uvod/Cilj. Atik holesteatom je epitelna cistična pseudotumorska izraslina u gornjem spratu bubne duplje. Hirurgija je jedino terapijsko rešenje za atik holesteatom. Cilj rada bio je da se analiziraju hirurški i audiološki rezultati nekoliko tehnika timpanoplastike koje smo koristili u hirurškom lečenju bolesnika sa atik holesteatomom. Naša hipoteza je bila da timpanoplastika sa rekonstrukcijom lateralnog zida atika uz pomoć hrskavice/kosti daje bolje rezultate nego timpanoplastika sa rekonstrukcijom lateralnog zida atika uz pomoć samo temporalne fascije. **Metode.** Ova retrospektivna studija obuhvatila je 80 bolesnika sa atik holesteatomom, starosti od 16 do 65 godina, kojima je urađena tim-

The independent and paired samples *t*-test of air conduction and air-bone gap were used to compare the results of preoperative and postoperative hearing tests. **Results.** The differences between hearing measurements of the two groups according to preoperative and postoperative auditory thresholds of the air conduction and the air-bone gap were considered no statistically significant. The difference between the two groups regarding to recurrent attic retraction pocket appearance and recurrence of cholesteatoma was considered statistically significant and the results were much better in the group I of the operated patients with cartilage/bone lateral attic wall reconstruction. **Conclusion.** “Wall up” tympanoplasty for attic cholesteatoma with lateral attic wall reconstruction leads to good anatomical and audiological results. A significant hearing improvement was obtained in both the types of lateral attic wall reconstructions in this study. Reconstruction with cartilage or mastoid cortex bone showed favorably long-term functional and anatomical results compared to primary tympanoplasty using only temporal fascia for lateral attic wall reconstruction in cases of attic cholesteatoma.

Key words:
cholesteatoma, middle ear; tympanoplasty; otologic surgical procedures; recurrence; hearing; treatment outcome.

panoplastika sa čuvanjem zadnjeg zida zvučnog voda i sa rekonstrukcijom lateralnog zida atika u opštoj endotrahealnoj anesteziji u Klinici za otorinolaringologiju Vojnomedicinske akademije u Beogradu u periodu 2006–2010. godine. Bolesnici su razvrstani u dve grupe prema tipu rekonstrukcije lateralnog zida atika i to: grupu I činilo je 60 operisanih bolesnika sa rekonstrukcijom lateralnog zida atika uz pomoć hrskavice/kosti i temporalnom fascijom; grupu II činilo je 20 operisanih bolesnika sa rekonstrukcijom lateralnog zida atika uz pomoć samo temporalne fascije. Postoperativno praćenje bolesnika sprovedeno je tokom perioda od najmanje 5 godina nakon operacije. χ^2 -test je korišćen za upoređivanje postoperativnih rezultata u obe grupe bolesnika sa rekonstrukcijom lateralnog zida atika, *t*-test za vaz-

dušnu vodljivost i vazdušno-koštanu razliku čujnosti je korišćen za upoređivanje preoperativnih i postoperativnih rezultata kod sluha svih bolesnika. **Rezultati.** Nije ustanovljena statistički značajna razlika u čujnosti bolesnika obe grupe prema preoperativnim i postoperativnim nalazima praga sluha za vazdušnu vodljivost i vazdušno-koštanu razliku čujnosti. Utvrđena je stistički značajna razlika u ponovnoj pojavi atik retrakcionog džepa i pojavi recidivantnog holesteatoma između dve grupe bolesnika, sa boljim postoperativnim rezultatom u grupi bolesnika sa rekonstrukcijom lateralnog zida atika uz pomoć hrskavice/kosti i temporalne fascije. **Zaključak.** Timpanoplastikom, tehnikom sa čuvanjem zadnjeg zida zvukovoda i rekonstrukcijom lateral-

nog zida atika, postižu se dobri anatomske i audiološki rezultati u operacijama atik holesteatoma. Značajno poboljšanje sluha je postignuto u oba tipa rekonstrukcije lateralnog zida atika u našoj studiji. Rekonstrukcija lateralnog zida atika uz pomoć autografta hrskavice ili kosti korteksa mastoida daje bolje dugoročne funkcionalne i anatomske rezultate nego timpanoplastika koja koristi samo temporalnu fasciju za rekonstrukciju lateralnog zida atika.

Ključne reči:
uvo, srednje, holesteatom; timpanoplastika; hirurgija, otološka, procedure; recidiv; sluh; lečenje, ishod.

Introduction

Attic cholesteatoma is keratin-producing squamous epithelium cyst (sac) in the epitympanum with or without spread in the mastoid or in the other parts of the middle ear¹. Attic cholesteatoma is a chronic disease of the middle ear which resorbs bone. Attic cholesteatoma can damage hearing and vestibular function and sometimes leads to extracranial and endocranial life-threatening complications. Not a single theory has been able to explain the clinical characteristics of all cholesteatoma types including attic cholesteatoma: uncoordinated hyperproliferation, invasion, migration, altered differentiation, aggressiveness and recidivism². According to invagination theory of primary acquired cholesteatoma development, the pathogenesis of attic cholesteatoma has the following characteristics: Eustachian tube dysfunction; poor aeration of the epitympanic space; retraction of the *pars flaccida*; normal migratory pattern altered; accumulation of keratin, enlargement of the sac³.

The early attic retraction pocket appearance signifies the beginning of attic cholesteatoma¹. Mirko Tos published "Classification of the attic retraction pocket" in 1980 and it is still valid nowadays^{4,5}. Tos and Poulsen⁴, and Sudhoff and Tos⁵ established four stages of *pars flaccida* retraction development. The stages are: stage I (*pars flaccida* is not adherent to the malleus); stage II (*pars flaccida* is adherent to the malleus); stage III (hidden retraction pocket); stage IV (hidden retraction pocket with erosion of outer attic wall-scutum).

For all these stages in classification of the attic retraction pocket, especially for the stage IV, we can say that there is a possibility for attic cholesteatoma occurrence, known as „potential“ cholesteatoma. The next step in attic cholesteatoma development is the accumulation of keratin (debris) in the attic retraction pocket with the possibility to clean it. If it is not possible to clean the debris (debridement) from the middle ear, then we can say that it is „dry“ cholesteatoma. „Wet“ cholesteatoma with periodical or constant otorrhea on the sick ear appears after infection with germs on „dry“ cholesteatoma. How to manage early attic retraction pocket and prevent attic cholesteatoma occurrence is still an unsolvable task for otologists. Retraction pocket is a precursor for recurrence of cholesteatoma, too.

Otomicroscopy finding is almost enough to diagnosticate attic cholesteatoma. Several diagnostic procedures can also help to establish the final diagnosis of attic cholesteatoma: ear endoscopy, hearing tests, imaging – Schuller's view X ray, temporal bone computed tomography (CT), cone beam CT⁶. Surgery is still the only therapeutic treatment for attic cholesteatoma. The objectives of attic cholesteatoma surgery are to: remove the cholesteatoma for cured dry ear; restore or maintain functional capacity of the ear; maintain normal anatomy (if possible); manage complications as priority.

Each case should be treated individually according to the extent/location of cholesteatoma and preoperative counseling. Preoperative counseling with a patient about the advantages and disadvantages of various types of surgery is necessary. There are two types of attic cholesteatoma surgery: canal "wall down" tympanoplasty; canal "wall up" tympanoplasty with the reconstruction of lateral attic wall "mur de loge".

There are many disadvantages of canal "wall up" tympanoplasty. It is technically more difficult, staged operation is often necessary, residual cholesteatoma is harder to detect, but this type of tympanoplasty maintains normal anatomy and restores function of the operated ear without water precaution. If it is necessary to wear hearing aid, it is easier to fit it in the canal "wall up" than in the canal "wall down" operated ears.

The aim of this study was to analyze the surgical and audiological results in tympanoplasties that use a logical application of several techniques for the management of attic cholesteatoma.

Methods

This retrospective clinical study included 80 patients, aged 16–65 years, with attic cholesteatoma (Figure 1) undergoing canal "wall up" tympanoplasty with lateral attic wall reconstruction under general anesthesia in the Ear, Nose and Throat (ENT) Clinic, Military Medical Academy (MMA) in Belgrade, between 2006 and 2010. A modification of the lateral attic wall reconstruction in cases of attic cholesteatoma was accompanied by ossiculoplasty when it was necessary. A computerized otologic database and patient charts were used to obtain the necessary data. There were different kind of at

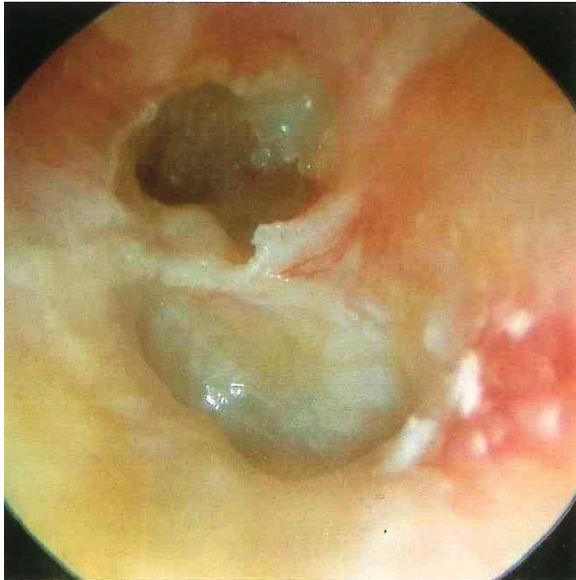


Fig. 1 – Otomicroscopy finding of attic cholesteatoma.

tic cholesteatoma extension in the middle ear. Among 80 operated patients, 19 had attic cholesteatoma localized in the epitympanic space with or without expansion in the antrum or in the Prussak's space with complete ossicular chain with or without ossicular fixation. In the other cases (61/80) attic cholesteatoma spreaded from the attic to the antrum, mastoid process or in the cavum tympani causing ossicular interruption. The most common was the damage of the long process of the incus or the damage of the other part of the incus (59/80), followed by the damage of the stapes (26/80) and the damage of the malleus (8/80). We made ossiculoplasty in the most of the operated patients (61/80) to reconstruct the sound conducting mechanism. We performed one of the types of the ossiculoplasty: incus interposition (37/80), malleostapedopexy (12/80), malleoplatinopexy (4/80), partial ossicular replacement prosthesis (PORP) (6/80) and total ossicular replacement prosthesis (TORP) (2/80). In all the cases with cholesteatoma affected incus, we used remodeling head of the malleus (4/37), interposed mastoid cortex bone (4/37), or interposed auricular cartilage (2/37) for the collumela effect instead of the incus.

The patients were divided into two groups according to the types of lateral attic wall reconstruction. Modification of one piece or the palisade technique was utilized for lateral attic wall reconstruction in cases of attic cholesteatoma (the group 1) (Figure 2): 1a) *tragus perichondrium*/cartilage island flap or; 1b) auricular cartilage with temporal fascia or 1c) mastoid cortex bone with temporalis fascia or the group 2: only temporal fascia. Postoperative follow-up examinations were done at least 5 years after the surgery. The first follow-up examination was two weeks after the surgery, then a month later and continued every three months during two years, and twice a year later on, if the postoperative period was neat. Our study was based on the otomicroscopy findings and a hearing test: audiometry with/without tympanometry and cone beam computed tomography (CT) of the temporal bones if necessary (Figure 3). Normal postoperative otomicroscopy finding or recurrent attic retraction pocket appearance or recurrence of cholesteatoma were recorded for

each patient. The χ^2 -test was used to compare postoperative sequelae for the two groups of the operated patients with lateral attic wall reconstruction. Hearing results were reported using four-frequency (500, 1000, 2000, 4000 Hz) pure-tone auditory thresholds and air-bone gap (PTA-ABG). The independent and paired samples *t*-test were used to compare the results of preoperative and postoperative air conduction and air-bone gap.

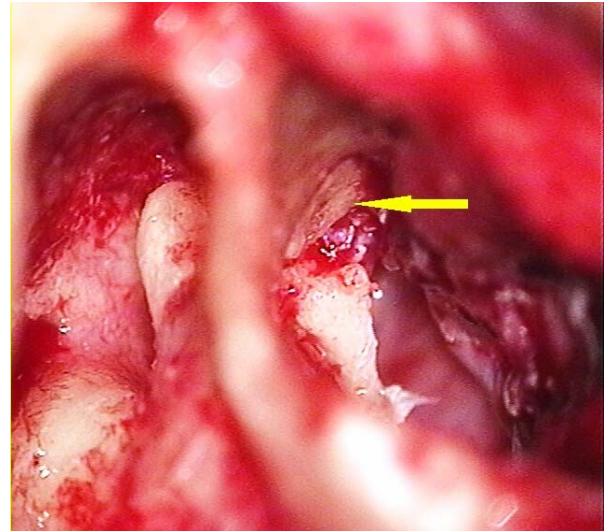


Fig. 2 – Intraoperative finding of lateral attic wall reconstruction with auricular cartilage (arrow shows shaped piece of auricular cartilage).

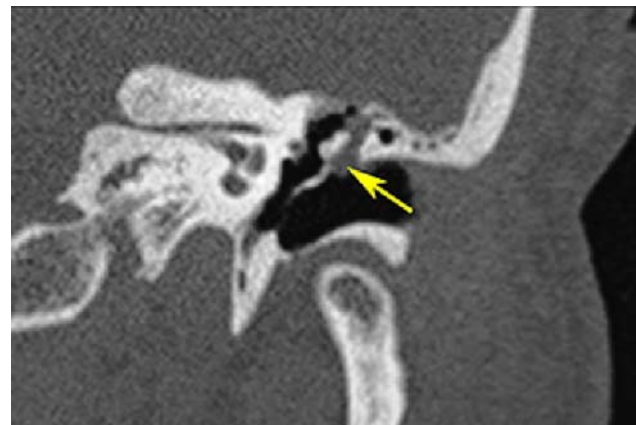

Fig. 3 – Cone beam computed tomography (CT) of temporal bone (arrow shows soft tissue of the attic cholesteatoma).

Results

We performed combined approach tympanoplasty with lateral attic wall reconstruction into 80 of the patients with histopathology verified attic cholesteatoma. The patients were divided in two groups according to the type of lateral attic wall reconstruction. The group I of 60 patients was operated with *tragus perichondrium*/cartilage island flap (10 patients), auricular cartilage with temporal fascia (42 patients), and mastoid cortex bone with temporalis fascia (8 patients). All 60 samples show almost similar hearing benefit and postoperative sequelae (Table 1). The group II of 20 patients was operated with only temporal fascia lateral attic wall re-

Table 1
Number of recurrent retraction pockets and relapse of cholesteatoma in the operated patients with lateral attic wall reconstruction of the middle ear

Recurrent/recidivism of disease	Lateral attic wall reconstruction (number of operated patients)			
	Tragus cartilage (10)	Auricular cartilage (42)	Bone (8)	Temporalis fascia only (20)
Recurrent attic retraction pocket	2	4	2	6
Recurrent/recidivism of cholesteatoma	2	5	2	8

construction. The average duration of the follow-up period was 72 months (ranging from 60–88 months). A total of 8 (13%) cases with recurrent attic retraction pocket and 9 (15%) cases with recurrence of cholesteatomas were noted in the group I, tympanoplasty with cartilage/bone lateral attic wall reconstruction during the follow-up. A total of 6 (30%) cases with recurrent attic retraction pocket and 8 (40%) cases with recurrence of cholesteatoma were noted in the group II, tympanoplasty with only temporal fascia lateral attic wall reconstruction (Table 1). The difference between the two groups according to recurrent attic retraction appearance was considered no statistically significant ($p = 0.090$, $p > 0.05$), but the difference between the two groups according to recurrence of cholesteatoma was considered statistically significant ($p = 0.023$, $p < 0.05$). The preoperative mean air conduction was 43.75 dB and the air-bone gap was 21.24 decibels (dB) including all the patients. The postoperative mean air conduction was 22.46 dB and the air-bone gap was 7.94 dB including all the patients. The preoperative mean air conduction in the group I tympanoplasty with cartilage or bone reconstruction of lateral attic wall was 46.30 dB, SD = ± 8.00 and air-bone gap was 21.72 dB, SD = ± 1.93 and the postoperative results were 24.29 dB, SD = ± 4.25 , 8.54 dB, SD = ± 0.82 , and respectively. The preoperative mean air conduction in the group II tympanoplasty with only temporal fascia reconstruction of lateral attic wall was 41.20 dB, SD = ± 2.28 , the air-bone gap was 20.76 dB, SD = ± 2.27 and the postoperative results were 20.63 dB, SD = ± 1.46 , and 7.33 dB, SD = ± 1.13 respectively (Table 2). The difference between preoperative and postoperative mean auditory thresholds in both groups separately was considered highly statistically significant ($p = 0.0001$, $p < 0.05$). The differences between hearing measurements of the two groups according to preoperative

and postoperative mean auditory thresholds of the air conduction and the air-bone gap were considered, no statistically significant ($p > 0.05$). There was no statistically significant difference in auditory improvement ($p = 0.305$) between group 1 (mean = 22.01dB, SD = ± 4.07) and the group 2 (mean = 20.57dB, SD = ± 1.09). There was no statistically significant difference in air-bone gap improvement ($p = 0.683$) between group 1 (mean = 13.18dB, SD = ± 1.26) and the group 2 (mean = 13.43dB, SD = ± 1.36).

Discussion

The incidence of recurrence of attic cholesteatoma is reported to vary (5–57%) according to data from the literature⁷. Canal “wall up” tympanoplasty with lateral attic wall reconstruction provides a good anatomical and hearing result for solving attic cholesteatoma, according to many surgeons^{8,9}. Many surgeons agree that lateral attic wall reconstruction with cartilage gives better anatomical result than lateral attic wall reconstruction with only temporal fascia according to the appearances of recurrence of attic cholesteatoma in a long period of time¹⁰. Actually, in our study, recurrence of cholesteatoma was rarely noted in a 5-year time in patients with cartilage lateral attic wall reconstruction (15%), contrary to only temporal fascia lateral attic wall reconstruction (40%). We used mastoid cortex bone for lateral attic wall reconstruction, except tragus or auricular cartilage, with equally good results. Whatever we use (cartilage or bone) for lateral attic wall reconstruction, the most important is to make it precisely to be fit for “*mur de loges*” reconstruction (Figure 4). There are no experiences with bone lateral attic wall reconstruction record in the “Pub Med” as we did with mastoid cortex bone.

Table 2
Preoperative and postoperative hearing measurements in both types of tympanoplasty

Group of patients	Hearing test	Air conduction (db), mean \pm SD	Mean air-bone gap (db), mean \pm SD	Statistical significance within the group	Statistical significance between the groups
Group I	Preoperative	46.30 \pm 8.00	21.72 \pm 1.93	$p < 0.000$	$p > 0.05$
	Postoperative	24.29 \pm 4.25	8.54 \pm 0.82		
Group II	Preoperative	41.20 \pm 2.28	20.76 \pm 2.27	$p < 0.000$	
	Postoperative	20.63 \pm 1.46	7.33 \pm 1.13		

Group I – patients with cartilage/bone lateral attic wall reconstruction; Group II – patients with only temporalis fascia lateral attic wall reconstruction.

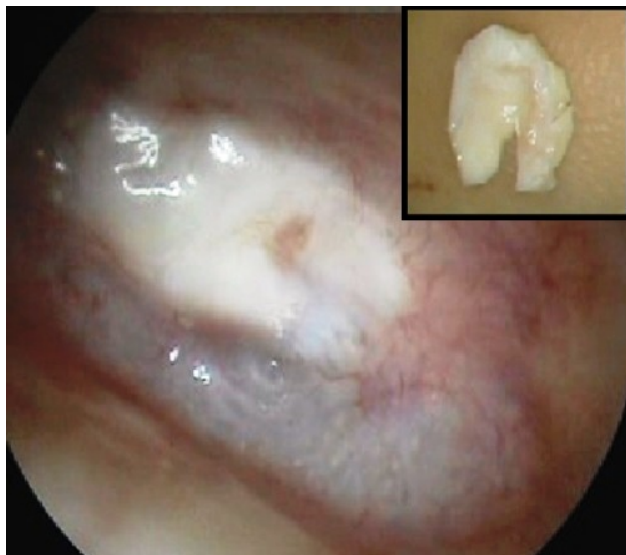

Fig. 4 – Postoperative otomicroscopy finding with a shaped piece of auricular cartilage for attic wall reconstruction of the middle ear.

A special issue is whether there is any chance to manage early attic retraction pocket before it becomes a surgery problem. Deep attic retraction pocket is an indication for surgery nowadays, according to some surgeons¹⁰, bearing in mind the fact that attic retraction pocket eventually leads to attic cholesteatoma appearance. How to manage the attic retraction pocket?

The Eustachian tube, epitympanic compartments and the anatomy of the atticotympanic diaphragm were examined to solve the problem of attic retraction pocket occurrence^{11,12}. Eustachian tube dysfunction has been linked with the middle ear pathology and attic cholesteatoma. One of the Eustachian tube dysfunction sequelae seen is *pars flaccida* retraction of the tympanic membrane. The findings confirmed that Prusak's space has a wide connection with the mesotympanum through the posterior pouch of Troeltsch's space and may have an additional narrow passage in its roof to the lateral malleal space¹³. The lateral incudomalleal fold regularly separates the upper lateral attic from the lower lateral attic and the mesotympanum. The medial incudal fold as a rule is atrophic already at birth. The anterior tympanic isthmus thus extends from the tensor tympani tendon to the posterior incudal ligament and is the main passage for epitympanic and mastoid aeration. Openings in the tensor fold area, when present, are also important¹¹. Otherwise, tensor fold resection together with the lateral incudomalleal fold can be used in the canal "wall up" tympanoplasty to improve attic aeration¹⁴.

In some ears, the posterior tympanic isthmus may form an auxiliary narrow route for aeration *via* the incudal fossa. Concern occurs when the unregulated middle ear and mastoid aeration with Eustachian tube dysfunction and atticotympanic blockade becomes a chronic problem, leading to the attic retraction pocket followed by debris collection and fulminate attic cholesteatoma.

In order to prevent attic retraction pocket, nowadays otologists can do the following: observation (frequent control, debridement); diagnostic procedures (ear endoscopy with 0° and 30° angle, hearing tests – audiometry and tympanometry, imaging – especially cone beam CT with quite good visualisation of the temporal bones and 1,000 times less radiation dose comparing to multislice computed tomography (MSCT)¹⁵ (Figure 2); aeration tube (T-tube maybe?) with N₂O insufflations (no statistical difference of attic cholesteatoma occurrence with or without implantation of aeration tube)¹⁶; endonasal dilatation/tuboplasty of the Eustachian tube. Preliminary results suggest that laser Eustachian tuboplasty is safe and efficient in the treatment of intractable Eustachian tube dysfunction according to some authors^{16,17}. Only a few otologists can say that a balloon Eustachian tuboplasty (BET) is a safe and effective treatment for improving Eustachian tube function and ear ventilation, but it remains to be seen in the future if it would help to prevent attic cholesteatoma occurrence^{16,18}, surgery for deep attic retraction pocket. Tympanoplasty for the correction of a retraction pocket if the *pars flaccida* can prevent further attic retraction and cholesteatoma development⁸. The question remains of is it necessary to operate deep attic retraction pocket if hearing is good and there is no otorrhea?

Conclusion

The attic cholesteatoma with a retraction pocket of the *pars flaccida* remains a difficult problem for the otologists to treat. It may lead to ossicular erosion and the interruption of ossicular chain causing difficult hearing loss. The type of tympanoplasty depends on the extent/location of cholesteatoma. A modification of the lateral attic wall reconstruction in cases of attic cholesteatoma was accompanied by ossiculoplasty when it was necessary. Tympanoplasty with lateral attic wall reconstruction leads to good anatomical and audiological results. A significant hearing improvement was accomplished in all the types of the lateral attic wall reconstructions. In attic cholesteatoma, tympanoplasty with lateral attic wall reconstruction using only one piece of cartilage or bone or the palisade technique resulted in precise reconstruction of the lateral attic wall, can prevent recurrent attic retraction development and help reduce recurrence of cholesteatoma. Reconstruction with cartilage or mastoid cortex bone showed better anatomical results compared to primary tympanoplasty using only temporal fascia for lateral attic wall reconstruction in cases of attic cholesteatoma. Postoperative hearing results were encouraging, too.

Acknowledgement

We wish to thank to all our colleagues and nurses in the ENT Clinic and the Institute of Pathology, Military Medical Academy, Belgrade, Serbia for helping us in this research.

R E F E R E N C E S

1. Lee JH, Hong SM, Kim CW, Park YH, Baek S. Attic cholesteatoma with tiny retraction of pars flaccida. *Auris Nasus Larynx* 2015; 42(2): 107–12.
2. Kuo C. Etiopathogenesis of acquired cholesteatoma: Prominent theories and recent advances in biomolecular research. *Laryngoscope* 2015; 125(1): 234–40.
3. Louw L. Acquired cholesteatoma pathogenesis: Stepwise explanations. *J Laryngol Otol* 2010; 124(6): 587–93.
4. Tos M, Poulsen G. Attic retractions following secretory otitis. *Acta Otolaryngol* 1980; 89(5–6): 479–86.
5. Sudhoff H, Tos M. Pathogenesis of attic cholesteatoma: Clinical and immunohistochemical support for combination of retraction theory and proliferation theory. *Am J Otol* 2000; 21(6): 786–92.
6. Alexander AE, Caldemeyer KS, Rigby P. Clinical and surgical application of reformatted high-resolution CT of the temporal bone. *Neuroimaging Clin N Am* 1998; 8(3): 631–50.
7. Kaylie DM, Gardner EK, Jackson C. Revision chronic ear surgery. *Otolaryngol Head Neck Surg* 2006; 134(3): 443–50.
8. Vashishth A, Mathur NN, Verma D. Cartilage palisades in type 3 tympanoplasty: Functional and hearing results. *Indian J Otolaryngol Head Neck Surg* 2014; 66(3): 309–13.
9. Yu LH, Lien CF. Tympanoplasty for pars flaccida. *Zhonghua Yi Xue Za Zhi (Taipei)* 1998; 61(8): 479–83.
10. Lin Y, Sun J. Surgical treatment to the attic in the middle ear cholesteatoma. *Lin Chung Er Bi Yan Hou Tou Jing Wai Ke Za Zhi* 2014; 28(21): 1633–5. (Chinese)
11. Palva T, Johnsson LG. Epitympanic compartment surgical considerations: Reevaluation. *Am J Otol* 1995; 16(4): 505–13.
12. Seibert JW, Danner CJ. Eustachian tube function and the middle ear. *Otolaryngol Clin North Am* 2006; 39(6): 1221–35.
13. Kashiba K, Komori M, Yanagihara N, Hinobira Y, Sakagami M. Lateral orifice of Prussak's space assessed with a high-resolution cone beam 3-dimensional computed tomography. *Otol Neurotol* 2011; 32(1): 71–6.
14. Palva T, Ramsay H. Chronic inflammatory ear disease and cholesteatoma: Creation of auxiliary attic aeration pathways by microdissection. *Am J Otol* 1999; 20(2): 145–51.
15. Struffert T, Grunwald IQ, Papanagiotou P, Politi M, Roth C, Reith W. Imaging of the temporal bone. An overview. *Radiologe* 2005; 45(9): 816–27.
16. Sudhoff H, Schröder S, Reineke U, Lehmann M, Korbmacher D, Ebmeyer J. Therapy of chronic obstructive eustachian tube dysfunction: Evolution of applied therapies. *HNO* 2013; 61(6): 477–82. (German)
17. Poe DS, Metson RB, Kujawski O. Laser eustachian tuboplasty: A preliminary report. *Laryngoscope* 2003; 113(4): 583–91.
18. Schröder S, Lehmann M, Sauzet O, Ebmeyer J, Sudhoff H. A novel diagnostic tool for chronic obstructive eustachian tube dysfunction—the eustachian tube score. *Laryngoscope* 2015; 125(3): 703–8.

Received on June 02, 2015.

Revised on September 03, 2015.

Accepted on November 25, 2015.

Online First July, 2016.